

# TOS NEWSLETTER



**Dr. G. Mukesh Mohan**  
*President TOS*



**Dr. J. Terrence Jose Jerome**  
*Secretary TOS*

## Welcome Message

*Be the change you want to see in the world" - Mahatma Gandhi.*

Dear All

It gives me great pleasure to meet you all through this inaugural issue of the Trichy orthopedic society newsletter. Trichy Orthopedic Society has been the pioneer for all innovation and excellence and remained one of the best ortho clubs in the Tamilnadu Orthopaedic Association. This newsletter, a feather to laurel, will be published monthly with lots of enthusing content. The secret of happiness always lies in sharing it. So, this letter will share our member's achievements, awards, honors, family member's success, social activities, academic programs, and all events of remembrance.

Keep reading! Keep us updating!

Looking forward  
**Dr. J. Terrence Jose Jerome**  
*Secretary, Trichy Orthopaedic Society*

# INAUGURATION OF THE NEW OFFICE BEARERS OF THE TRICHY ORTHOPAEDIC SOCIETY (TOS)

The new office bearers of the TOS took in charge during the CME on hip 360 held at Hotel Oxina in Trichy on 8th January 2023.



## NEW OFFICE BEARERS

**Dr. G. Mukesh Mohan**

*President TOS*

**Dr. J. Terrence Jose Jerome**

*Secretary TOS*

**Dr. G. Ramesh Prabu**

*Joint- Secretary TOS*

**Dr. I. Geethan**

*Treasurer TOS*

**Dr K. Balasubramanian**

*TNOA EC member Central zone- I*

### *Executive Committee members*

**Dr. S. Sokkalingam**

**Dr. R. Devendran**

**Dr. N. Ajit Kumar**

**Dr. L. Rajesh Kumar**

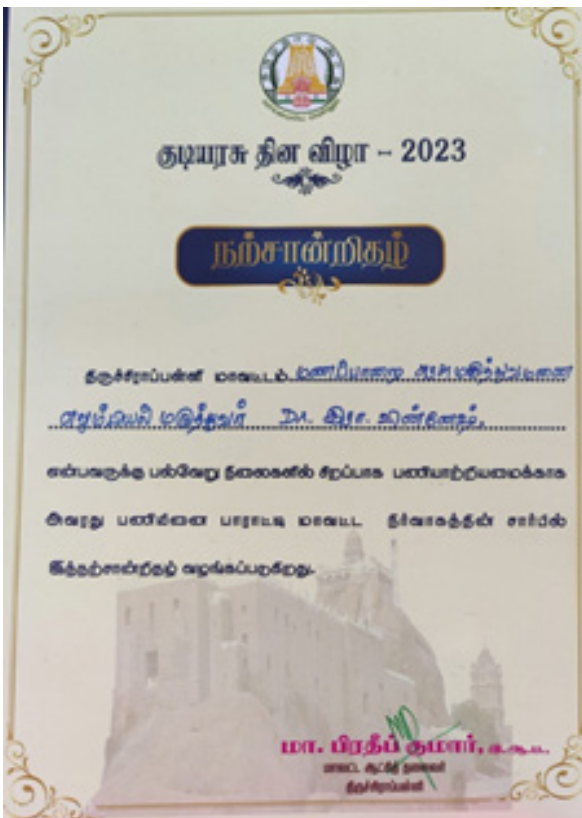# FIRST TOS EC MEETING AT TRICHY



The first executive meeting (EC) was held on 13th January 2023 at the Mukesh Arthrocare Hospital, Trichy. The EC has discussed and approved all vital decisions and year-long programs.

## TOS MEMBERS ACHIEVEMENTS

Prof. Dr. Kalyasundaram ( Head of the Department of Orthopaedics, KAPV Medical College, Trichy) and **Dr.G.Vignesh** (GH Manapparai) were awarded the Outstanding certificates from the Trichy District Collector on the eve of 26th January 2023 Republic Day celebrations.



# CME ON HIP 360

The TOS successfully conducted the CME on Hip 360 on 8th January 2023 in Hotel Oxina, Trichy. More than 100 participants and many faculties discussed the technical nuances, updates, and innovations on hip disorders. The Hip CME had witnessed a workshop in bone models about various fixation devices for hip



fractures. Dr. Leo Joseph, Dr. K. Senthil Kumar, Thanjavur, Dr. R. Ashok Kumar, Madurai were the invited faculty for the meeting. Dr. P. R. Ramasamy, Dr. V. J. Senthil, Dr. I. Geethan, Dr. S. Jaikish, Dr. K. Balasubramanian, Dr. S. Chockalingam, were the faculty of the TOS. Dr. Samson Daniel, Dr. Mathivanan, and other senior members honored the event. The CME fetched 2 credit hours from the Tamilnadu Medical Council.





IOA



OASIS



TNOA

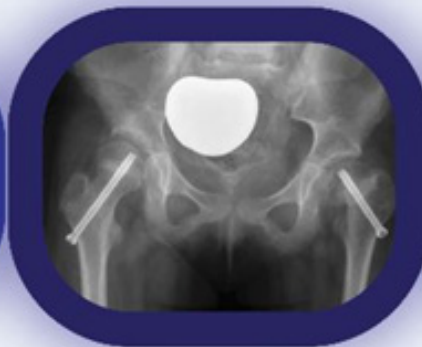
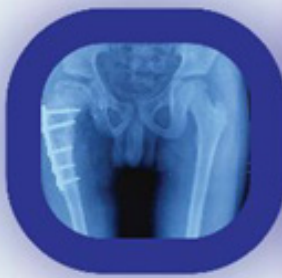
TOS



# HIP 360°

**LECTURES & CASE BASED PRESENTATIONS**



## VENUE

**Oxina Lygon**  
Salai Road, Trichy -18

## Date & Time:

**8<sup>th</sup> Jan 2023** between 10 am - 4 pm

**TNMC Credit Points Awarded**

Organized by

**Trichy Orthopaedic Society**

**Dr.S.Jaikish**  
President

**Dr.G.Mukeshmohan**  
Secretary

**Dr.K.Balasubramanian**  
TNOAEC Member

REGISTRATION MANDATORY (free registration)

# FRACTURE DISLOCATION OF HIP JOINT



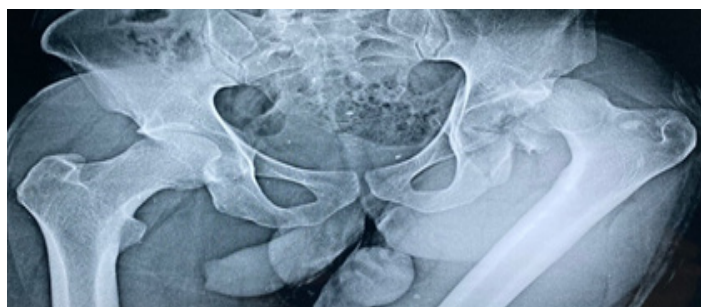Dr. L. Rajesh Kumar  
EC member, Trichy Orthopedic Society  
Orthopedic surgeon, Maruthi Hospital  
Trichy

## *Introduction:*

The weight bearing axis of the human body passes from the axial to the appendicular skeleton through the acetabulum. Thus fractures of the acetabulum tend to affect the eventual function of lower limbs. These fractures constitute about 0.6% of all skeletal injuries. Motor vehicular accidents are the major cause contributing to about 70% of these fractures. Until the middle of the 20th century, almost all cases of fracture acetabulum were treated non - operatively. The first experience with open reduction of acetabular fractures was reported in 1943. Subsequently with the progress made in the imaging techniques and osteosynthesis, acetabular fractures were increasingly appreciated and were more commonly subjected to surgical management.

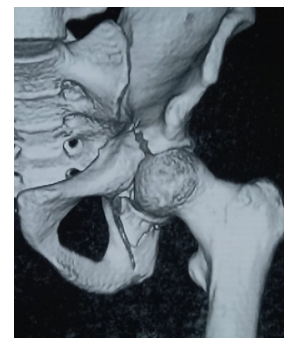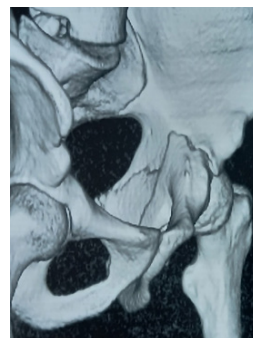
## *Case Presentation:*

Twenty five year old male patient was admitted to the casualty with history of RTA. He complained of pain and deformity of left hip. Radiograph showed fracture dislocation of left hip joint.

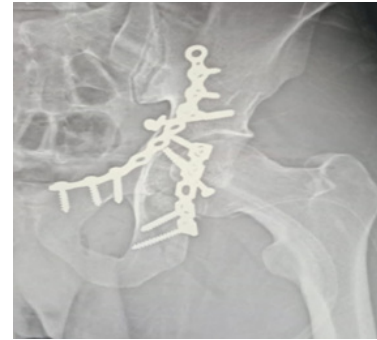
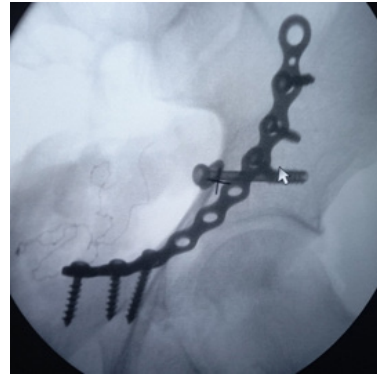


Closed reduction was done and CT Scan with 3D Reconstruction showed transverse fracture with associated posterior wall fracture. So planned open reduction and inter-

nal fixation of Acetabulum first by Stoppas approach for anterior column fixation followed by posterior column fixation by Kocher Langenbeck approach on the same day.



Post operative radiograph was satisfactory. Patient kept on bed rest for 3 weeks, bed side sitting and partial weight bearing mobilization started at 3rd and 6th week respectively. At 3rd post operative month patient was mobilized with full weight bearing. The surgical management gives good outcome in acetabular fractures, only if articular reduction is perfect and articular surface of the femoral head and the acetabulum are intact. Closed reduction of the dislocated hip prior to surgical intervention decreases the duration of surgery and also assist in better planning.



## PUBLICATIONS

Dr. J. Terrence Jose Jerome published his work about arthrodesis for habitual dorsal dislocation of the thumb metacarpophalangeal joint in the Journal of Orthopaedic Reports in January 2023.

ScienceDirect

View PDF

Journal of Orthopaedic Reports  
Available online 12 January 2023, 100134  
In Press, Journal Pre-proof

Case Report

Arthrodesis for habitual dorsal dislocation of the thumb metacarpophalangeal joint- A case report

J. Terrence Jose Jerome

Show more

Outline | Share | Cite

<https://doi.org/10.1016/j.jorep.2023.100134>

Get rights and content

Under a Creative Commons license ● Open access



Abstract

Background

Habitual dislocation of the thumb

FEEDBACK

sciendoirect.com

Follow Us on  

Drop your mails @ [toctrichy@gmail.com](mailto:toctrichy@gmail.com)

Visit Us @ <http://www.trichyos.com/web>